

## Supplement

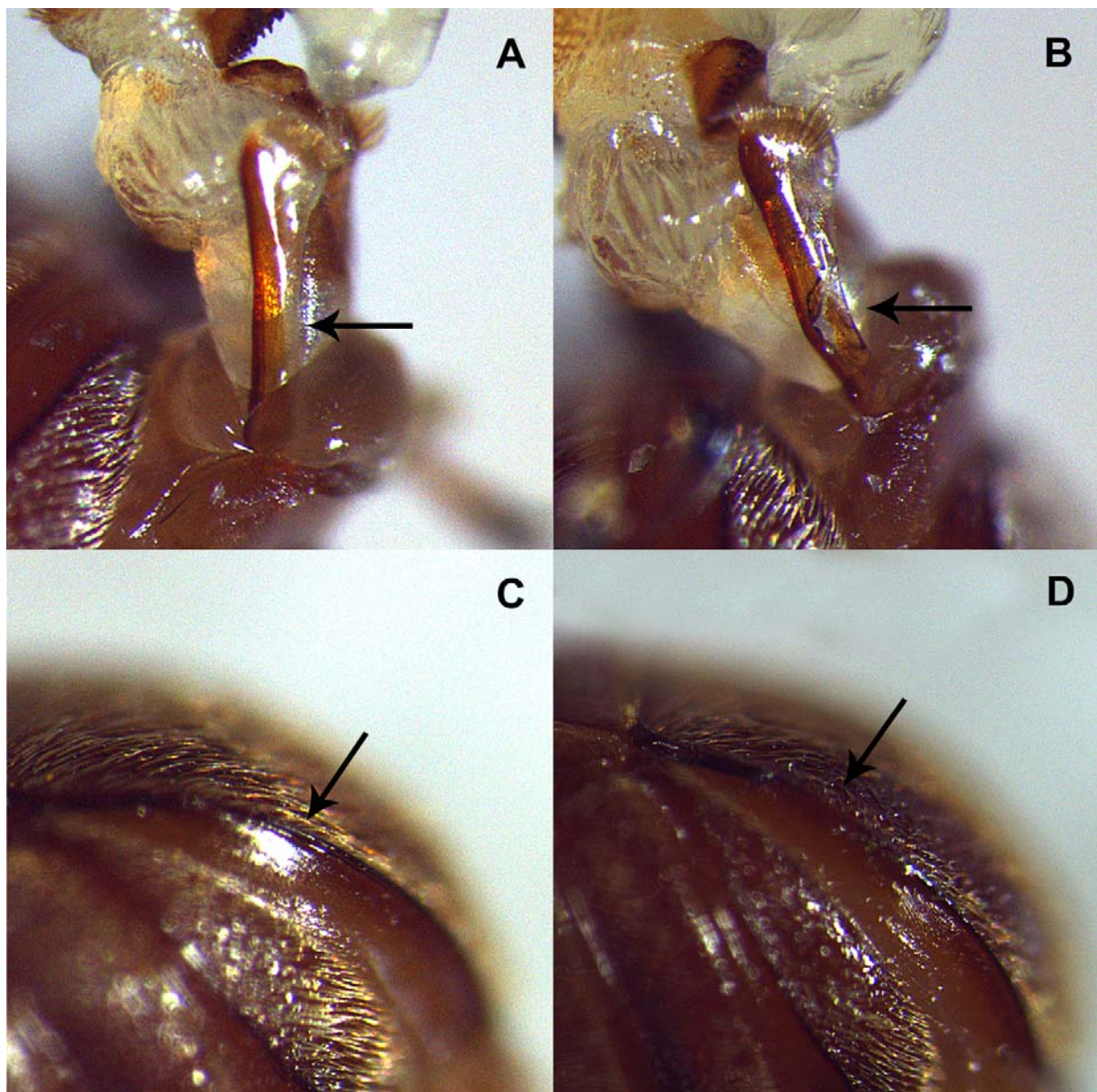


Fig. S1. **The two control treatments.** The parameres (A) were used to control for genital damage. The right paramere was therefore abraded by filing with a dentist drill (B). To control for genital ablation itself, an abdominal structure other than the genitalia was abraded, namely the pygidium (C). The rim of the left side of the pygidium was filed down (D).