

Clinical puzzle: Barrett's oesophagus

Massimiliano di Pietro¹, Christopher J. Peters¹ and Rebecca C. Fitzgerald^{1,*}

The incidence of oesophageal adenocarcinoma has increased dramatically in the Western world over the past two decades. Owing to its dismal 5-year prognosis in advanced stages, early diagnosis is required in order to improve survival rates. Barrett's oesophagus (Barrett's) has been recognised as a pre-cancerous condition generally associated with chronic and severe gastro-oesophageal reflux disease (GORD). Barrett's is defined as the substitution of the normal stratified squamous epithelium of the oesophagus with a columnar cell lining with intestinal-type differentiation; a phenomenon commonly referred to as intestinal metaplasia. Clinical challenges include finding cost-effective ways to identify patients with Barrett's, stratifying them according to their cancer risk and improving the diagnostic potential of endoscopic sampling. Research has generally focused on identifying tissue biomarkers to predict cancer risk in these patients. The oesophagus is easily accessible, making it possible to work with human samples, but most studies have been retrospective and underpowered. Endoscopic surveillance programmes are problematic due to sampling bias and the subjective grading of dysplasia. The lack of an animal model has hampered studies to elucidate markers of the transition from Barrett's to cancer and to test potential therapeutics. However, a number of in vitro model systems are ripe for further development into more physiologically complete systems.

The clinical issues of Barrett's oesophagus

The population prevalence of Barrett's oesophagus (Barrett's) is hard to determine, but studies suggest a general population prevalence of 1.6% in Sweden, increasing to 2.4% in those with reflux symptoms (Ronkainen et al., 2005). This is compared with 25% in asymptomatic American males over the age of 50 and undergoing screening for colorectal cancer (Gerson et al., 2002). Most cases remain undiagnosed, with one study suggesting that there are five unrecognised cases of Barrett's for every case identified (Conio et al., 2001). Barrett's is most commonly diagnosed in people under investigation for reflux symptoms, when approximately 4-10% will present with Barrett's (Corder et al., 1996). Owing to the widespread availability of acid-suppressant medications, many patients with reflux symptoms are not offered endoscopy unless they

have alarming symptoms and screening for Barrett's in patients with reflux symptoms is not routine practice due to its cost.

The diagnosis of Barrett's is complex. In the UK, the British Society of Gastroenterology defines Barrett's oesophagus as an endoscopically visible segment of columnar-lined oesophagus, which has been histopathologically verified (Playford, 2006). In contrast to US guidelines, intestinal metaplasia is not required in the UK (Sampliner, 2002). The development of cancer in Barrett's occurs via interim dysplastic stages. Dysplasia is defined as the presence of cytological and nuclear atypia, with or without architectural disruption, within the Barrett's oesophagus crypts (Ibrahim, 2000). Based on the severity of these changes dysplasia is scored as low-grade dysplasia (LGD) or high-grade dysplasia (HGD), which have a progressively

increasing risk of malignancy compared with non-dysplastic Barrett's. Unfortunately the distinction between HGD and LGD is subjective and there is considerable inter- and intra-operator variability (Kerkhof et al., 2007).

Patients with Barrett's have an approximately 30-125-fold increased lifetime risk of developing oesophageal adenocarcinoma (OAC) (Solaymani-Dodaran et al., 2004), with approximately a 0.5% risk of OAC each year they have the disease (Shaheen et al., 2000). With the exception of patients exhibiting HGD, which has the highest risk of transformation of OAC, it is difficult to identify which patients are likely to progress from Barrett's to cancer. The incidence of OAC is increasing rapidly (Powell et al., 2002; Younes, 2005) and the 5-year survival rate remains less than 20%. Earlier diagnosis should improve prognosis but the majority of tumours arise de novo and, therefore, there is limited opportunity to intervene early. Surveillance is a contentious issue due to the relatively low number of Barrett's patients developing OAC, combined with the capital expense and invasiveness of endoscopy. It is therefore difficult to justify the cost-benefit ratios of surveillance. Current UK guidelines advise endoscopy in non-dysplastic Barrett's oesophagus patients every 2 years (Playford, 2006); however, in reality, this practice varies widely. The widely accepted Seattle surveillance protocol, as developed by the internationally respected research group, specifies quadrant biopsies every 1-2 cm throughout the Barrett's segment, as well as above and below the segment. This clearly generates large numbers of specimens and is very labour intensive. Practical adoption of this system also varies considerably.

Historically, patients with HGD were offered open oesophagectomy (usually Ivor-Lewis) as the treatment of choice. This operation is associated with significant morbidity and mortality. For patients with disease confined to only the superficial layers of the oesophagus, a radical operation is not

¹MRC Cancer Cell Unit, Hutchison-MRC Research Centre, Hills Road, Cambridge, CB2 0XZ, UK

*Author for correspondence (e-mail: rcf@hutchison-mrc.cam.ac.uk)

required and, therefore, alternative less invasive options are being explored. These include endoscopic techniques, such as mucosal resection (Bergman, 2005), photodynamic therapy (Bergman, 2005) and radiofrequency ablation (Sharma et al., 2007), or a minimally invasive surgical intervention (Fernando et al., 2002). Unfortunately, these techniques have been introduced before any data from large-scale randomised trials and long-term outcome studies has been made available. Whether they have a role in Barrett's patients prior to the development of dysplasia has not been demonstrated.

Barrett's oesophagus presents an important research topic. It is rising in incidence and OAC is now the most common oesophageal malignancy in the Western world (Bollschweiler et al., 2001). It is an attractive research area since the oesophagus is relatively easy to access and the clear metaplasia-dysplasia-carcinoma sequence allows longitudinal monitoring over time (in contrast to pancreatic lesions, which are hard to access, and colonic polyps, which are removed). Better understanding of the molecular changes leading both to the development of Barrett's and its progression to OAC may translate into new therapeutic targets. There is also potential for Barrett's to serve as a surrogate to other epithelial cancers with a premalignant stage (intraepithelial neoplasia).

Genetic predisposition to Barrett's oesophagus

An important issue raised by the clinical case presented here is the significance of a family history of Barrett's in the approach to patients with gastro-oesophageal reflux disease (GORD) symptoms. Environmental factors, such as dietary components that augment gastro-oesophageal reflux, increased body-mass index and eradication of *Helicobacter pylori*, play a role in the aetiology of Barrett's. However, similarly to other diseases it is likely that the impact of these environmental elements is stronger in genetically predisposed individuals (Fitzgerald, 2006). For example, as Barrett's is believed to result from exposure of the oesophageal epithelium to luminal toxic agents, differential expression of the enzymes involved in detoxification processes may influence susceptibility to Barrett's carcinogenesis.

Case study

A 61-year-old male with a history of reflux symptoms extending over several years was referred for a screening endoscopy as part of a research programme. His past medical history included an X-ray diagnosis of hiatus hernia and a recent myocardial infarction. The family history was significant for Barrett's, in that his brother had recently been diagnosed with HGD, which was treated endoscopically with photodynamic therapy. The screening endoscopy revealed that a 3 cm circumferential segment of Barrett's (Prague classification C3-M5) was confirmed, histologically, to contain intestinal metaplasia (IM) and LGD. Six months later, focal LGD was confirmed and 6 months after that endoscopic biopsies revealed evidence of HGD in the distal part of the segment in the absence of a macroscopic lesion. It is recommended that high-grade changes are confirmed on two independent occasions and the subsequent confirmatory endoscopy revealed a subtle multi-nodular area in the distal oesophagus, with pathological features of adenocarcinoma in situ. Endoscopic ultrasound (EUS) demonstrated irregularity of the submucosal layer in the nodular region, which was used to guide an endoscopic mucosal resection. The resected lesion revealed evidence of LGD with possible HGD at the margins. There was no evidence of invasion. The case was discussed by the regional multidisciplinary team for oesophagogastric cancer, where it was felt that the patient should be offered a choice of therapy - either minimally invasive oesophagectomy or radiofrequency ablation. The patient opted for radiofrequency ablation.

Recent data have suggested an association between polymorphisms of two detoxifying enzymes [NAD(P)H:quinone oxidoreductase and glutathione S-transferase P1] and the risk of developing Barrett's and OAC (Casson et al., 2006; di Martino et al., 2007; Redon et al., 2006). Another candidate genetic marker of Barrett's susceptibility is cyclin D1, whose function as part of the cell cycle machinery is to allow progression to S-phase. Over-expression of cyclin D1 protein has been documented in Barrett's and OAC (Arber et al., 1996). Two different North American reports (Casson et al., 2005; Izzo et al., 2007) have analysed the role of the single nucleotide polymorphism G/A870, which is associated with an alternative-spliced protein variant with an increased half-life, in oesophageal carcinogenesis (Crane et al., 2007). This genotype was found to be responsible for increased susceptibility to GORD, Barrett's and OAC in the general population, with a more aggressive phenotype observed. Unfortunately these findings were not confirmed in a subsequent German study (Geddert et al., 2002). Overall, data on a genetic predisposition to Barrett's remain scarce and are still not conclusive. Larger prospective studies with careful definition of cases and controls are needed to draw conclusions on the association of a specific genotype, with the risk of developing Barrett's or increasing the likelihood for progression to OAC. Even if we could identify individuals at risk of this disease at the current time, management of these individuals would rely on endoscopic surveillance, which has a complex list of shortcomings that are described below.

Early diagnosis and biomarkers of progression

Accurate diagnosis of dysplasia through surveillance is particularly problematic. Owing to histopathological heterogeneity, biopsies are prone to sampling bias and may not accurately represent the entire Barrett's segment. This is a difficulty highlighted by this case study. There has been interest in using endoscopic dyes (methylene blue and acetic acid) to target biopsies in order to increase the yield of IM and dysplasia in the sampling material; however, the results have been disappointing except in expert hands (Canto et al., 2001; Fortun et al., 2006). New imaging technologies [narrow-band imaging (NBI) and autofluorescence] have recently been introduced to improve the diagnostic power of endoscopy. They are based on the use of special filters that manipulate the white light and allow better characterisation of the mucosal pattern and recognition of early neoplasia (Curvers et al., 2008). The combination of NBI and autofluorescence with high-resolution endoscopy and optical techniques, such as elastic scattering spectroscopy, are being evaluated with encouraging initial data (Lovat et al., 2006). This is an area ripe for further research.

A further issue concerns the subjective nature of dysplasia grading. Biomarkers to stratify patients according to their risk of progression to cancer would be extremely beneficial. For example, in the late 1990s, it was shown that in a group of 61 Barrett's patients, the expression of p53 in Barrett's predicted the risk of progression to HGD and OAC (Younes et al., 1997). More

recently, a nested case-control study found that the odds ratio (OR) for diffuse and intense immunostaining of p53 in biopsies from Barrett's patients who developed cancer, was higher than in control patients (OR 11.7); however, this only applied to 30% of cases. Therefore, the sensitivity was too low to inform clinical practice (Murray et al., 2006). Reid and co-workers, who run the Seattle Barrett's oesophagus research programme, have performed comprehensive molecular analyses on samples from their prospective cohort, which have overcome the limitations of immunostaining for determining p53 status. The latest study reported by this group (Galipeau et al., 2007) demonstrated that even though loss of heterozygosity (LOH) at the p53

locus 17p alone was able to significantly predict this risk [risk ratio (RR) 10.6], the association with other markers (9p LOH and DNA content abnormality) was highly predictive (RR 38.7). There is also interest in epigenetic markers of progression. A study that compared 45 non-progressors with eight progressors found that hypermethylation of p16, Runt-related transcription factor 3 (RUNx3) and hyperplastic polyposis gene 1 (HPP1) was associated with an increased likelihood of developing HGD or OAC (OR 1.74, 1.80 and 1.77, respectively) (Schulmann et al., 2005). Other promising predictors are markers of cell proliferation, such as cyclin D1, minichromosome maintenance complex 2 (MCM2) and cyclin A (Bani-Hani et al., 2000; Lao-Sirieix et al., 2007; Sirieix et al., 2003).

Currently none of these biomarkers has been adopted into routine clinical practice, because, according to the Early Detection Research Network (EDRN) criteria (Pepe et al., 2001), large multicentre trials are required to confirm the results. The development of imaging methodologies that combine the knowledge of biomarkers for dysplasia with advanced optical tools for the early endoscopic detection of dysplasia should be possible within the rapidly evolving field of molecular imaging (Brindle, 2008). One potential hurdle is the variability in the timing and nature of genetic events driving cells to dysplasia.

Research models and their impact on investigating novel therapeutic approaches

The work published on the involvement of cyclooxygenase-2 (COX-2) in Barrett's-associated carcinogenesis can be used to demonstrate how experimental models have generated a platform leading to the initiation of clinical trials (Fig. 1).

There are currently no animal models for Barrett's; therefore, in vitro models have been widely used to attempt to understand the molecular basis of carcinogenesis. In primary oesophageal epithelial and fibroblast cell cultures from Barrett's patients, treatment with a COX-2 inhibitor effectively blocked cell proliferation (Buttar et al., 2002a). These models (cell lines or primary cultures) enable a variety of straightforward experimental data to be obtained, ranging from viability and apoptosis, to tracking intracellular molecules and quan-

tifying transcripts and proteins. Unfortunately, cells grown in a monolayer are devoid of the conditions and interactions that they would be subject to in their natural environment. Their growth behaviour can be heavily affected by immortalisation procedures and cell lines successfully propagated in culture are subjected to artificial selection pressures.

In order to overcome some of the disadvantages of monolayer cultures, organotypic cultures have been proposed as a research tool. These are multilayered structures, established from a monolayer of epithelial cells, cultured on special matrices enriched with collagen and fibroblasts. Oesophageal organotypic cultures closely resemble the in vivo epithelium (Oda et al., 1998). However, this experimental model lacks glandular differentiation and contains an inadequate stromal environment. This drawback is crucial because, although the cell type originating from the intestinal metaplasia has yet to be identified, we, and others, have provided evidence that it is likely to reside in the submucosal compartment (Chang et al., 2007; Leedham et al., 2008). As a matter of fact, oesophageal organotypic cultures have been more productively exploited in the field of squamous cell carcinoma, which arises within the squamous epithelium (Okawa et al., 2007), rather than adenocarcinoma. As an alternative approach, ex vivo cultures permit the study of oesophageal cells in their original environment and are easily established using widely available tissue from endoscopic procedures. For example, exposure of ex vivo cultured cells, from normal and pathologic human oesophageal biopsies, to damaging agents (acidic pH and bile salts) significantly increased COX-2 expression, confirming results seen in Barrett's patients (Shirvani et al., 2000). Unfortunately, endoscopic biopsies can only be kept in culture for a short period of time (up to 72 hours), meaning that they cannot be used to address complex temporal questions.

In the context of developing novel therapeutics, animal models for cancer are frequently of considerable value. Unfortunately, rodents present several drawbacks to the engineering of a reliable model of oesophageal carcinogenesis. Firstly, in contrast to the human, the rodent oesophageal epithelium is keratinised and lacks submucosal glands. Secondly, the gastro-

Clinical terms

Barrett's oesophagus (Barrett's) – a pre-cancerous condition arising from morphological changes in the cells lining the oesophagus, from squamous epithelia to columnar, associated with chronic gastro-oesophageal reflux

Carcinoma – an invasive and malignant tumour of epithelial origin

Dysplasia – a localised, abnormal growth of cells, indicating a pre-cancerous, and usually treatable, condition

Endoscopy – a procedure where an optical instrument is used to visualise body tubes or cavities

Metaplasia – the transformation of cells from one type to another; in Barrett's, this usually refers to the abnormal change of squamous cells into columnar epithelia

Neoplasia – the formation of new tissue, which may be either benign or malignant

Oesophageal adenocarcinoma (OAC) – malignancy of the oesophagus originating from the epithelial lining of a gland. Its incidence is increasing faster than any other cancer type in the Western world

Photodynamic therapy

(photochemotherapy) – tissues are chemically sensitised to light via oral administration of porfimer sodium or 5-aminolevulinic acid, which accumulate preferentially in abnormal tissues. These are inactive until exposed to light from a red laser that makes them cytotoxic. One side effect of this treatment experienced by patients is a general sensitivity to light, lasting up to 6 weeks

Radiofrequency ablation – the use of an electrode to deliver a rapid, high powered, preset amount of radiofrequency energy directly to the neoplastic Barrett's tissue. This is a very recently developed treatment method and little is known about long-term safety

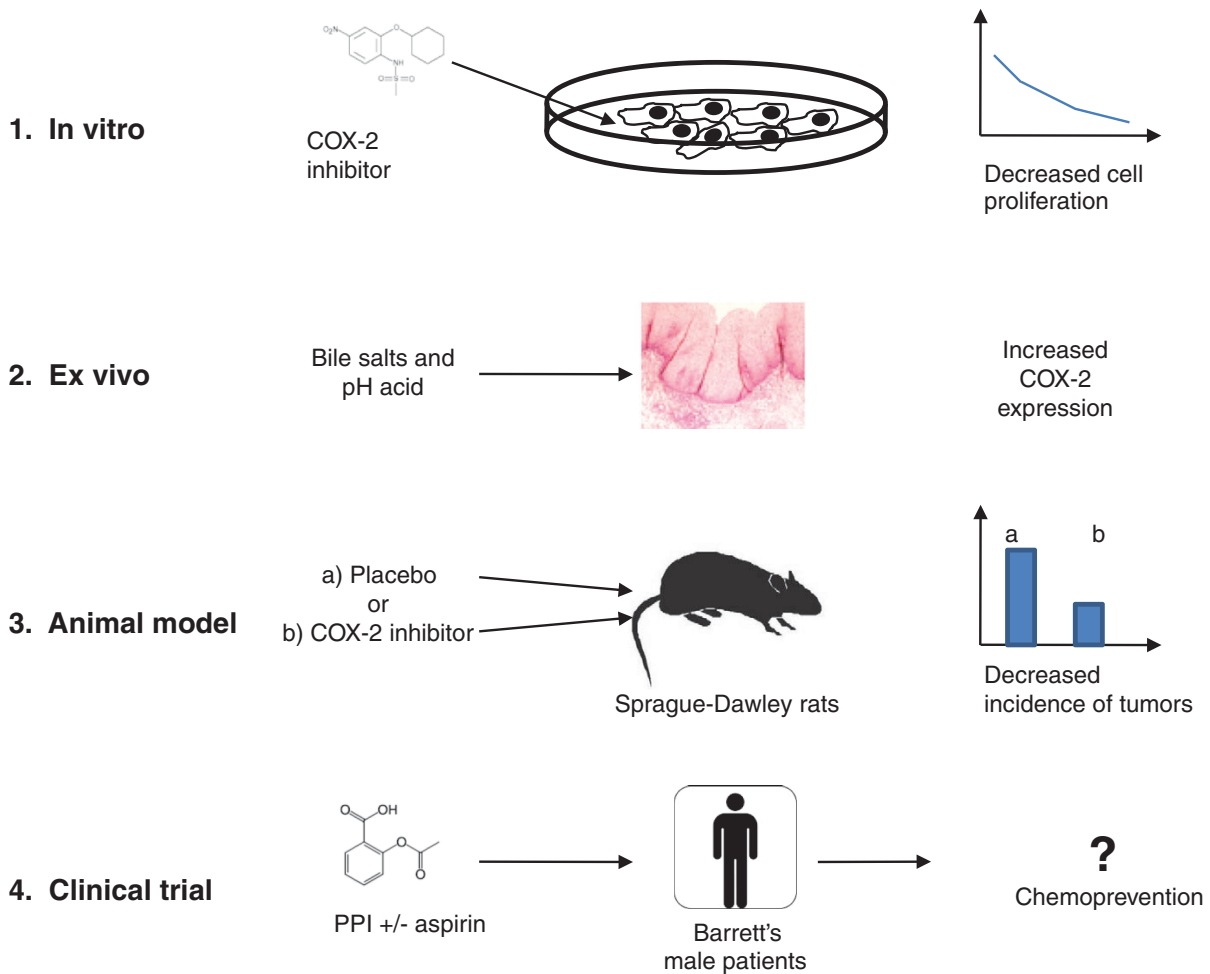


Fig. 1. Schematic representation of the multi-step research approach that was used to investigate the role of COX-2 in oesophageal cancer and supported an ongoing clinical trial. (1) Treatment of in vitro cultured cells with the COX-2 inhibitor NS-398 diminishes the proliferation rate, suggesting that high COX-2 activity supports cell growth. (2) Exposure of ex vivo cultured Barrett's oesophagus biopsies established a correlation between over-expression of COX-2 and the chemical damage induced by gastro-oesophageal reflux. (3) In rats surgically predisposed to oesophageal cancer by oesophago-jejunostomy, COX-2 inhibition is sufficient to reduce the incidence of oesophageal tumours. (4) The ongoing AspECT clinical trial aims to assess the chemopreventive potential of the COX-2 inhibitory effect of aspirin in Barrett's oesophagus.

oesophageal junction differs anatomically from humans, in that it has a more distal location and is in closer proximity to the pylorus. In addition, the generation of a genetically modified murine model has been hindered so far by the absence of an identified gatekeeper mutation, like adenomatous polyposis coli (APC) or K-Ras in colonic and pancreatic malignancies, respectively (Frese and Tuveson, 2007). Finally, research has currently failed to identify an oesophageal-specific promoter to engineer suitable transgenic animals. Therefore, the only animal models hitherto developed are based on surgical manipulation of the upper GI tract. Indeed, in a rat model of gastro-oesophageal reflux,

where a surgical oesophago-jejunostomy predisposes animals to Barrett's and OAC, treatment with COX-2 inhibitors significantly reduced the risk of OAC, suggesting a direct correlation between COX-2 activity and progression from Barrett's to cancer (Buttar et al., 2002b). The cumulative evidence of COX-2 involvement in this disease has led to clinical chemoprevention trials. The multicentre Aspirin Esomeprazole Chemoprevention (AspECT) study of proton pump inhibitors with or without aspirin should clarify whether pre-clinical data from different research models have been reliable. Ultimately, the clinical data are what matter in order to improve outcomes for patients.

In conclusion, more comprehensive knowledge of the disease mechanisms driving the onset of intestinal metaplasia in the oesophagus, and its progression to cancer, is needed to halt the dramatically rising incidence of OAC. Basic research is needed to provide novel insights into the molecular events supporting the phenotypic changes and animal models are required to replicate the human disease in a model system. This will support translational research in the attempt to find biomarkers of progression and novel therapeutics.

AUTHOR CONTRIBUTION

M.D.P., C.J.P. and R.C.F. were all responsible for planning the content of this article. C.J.P. was

Clinical and basic research opportunities

- The identification of early biomarkers that are indicative of the disease and later biomarkers that stratify patients in terms of their risk for progression
- More cost-effective screening methods for diagnosis and monitoring
- Standardised criteria for recognising and grading dysplasia
- An understanding of the mechanisms resulting in the de novo origin of most Barrett's associated tumours
- A genetically tractable model organism and/or the identification of a model organism with a gastrointestinal physiology that is capable of recapitulating the pathology of Barrett's

responsible for carrying out the literature review for the clinical issues section whereas M.D.P. was responsible for literature reviews for the other sections. All three authors were responsible for preparation of the manuscript and its approval prior to submission.

COMPETING INTERESTS

The authors declare no competing financial interests.

REFERENCES

- Arber, N., Lightdale, C., Rotterdam, H., Han, K. H., Sgambato, A., Yap, E., Ahsan, H., Finegold, J., Stevens, P. D., Green, P. H. et al. (1996). Increased expression of the cyclin D1 gene in Barrett's esophagus. *Cancer Epidemiol. Biomarkers Prev.* **5**, 457-459.
- Bani-Hani, K., Martin, I. G., Hardie, L. J., Mapstone, N., Briggs, J. A., Forman, D. and Wild, C. P. (2000). Prospective study of cyclin D1 overexpression in Barrett's esophagus: association with increased risk of adenocarcinoma. *J. Natl. Cancer Inst.* **92**, 1316-1321.
- Bergman, J. J. (2005). Endoscopic treatment of high-grade intraepithelial neoplasia and early cancer in Barrett oesophagus. *Best Pract. Res. Clin. Gastroenterol.* **19**, 889-907.
- Bollschweiler, E., Wolfgarten, E., Gutschow, C. and Holscher, A. H. (2001). Demographic variations in the rising incidence of esophageal adenocarcinoma in white males. *Cancer* **92**, 549-555.
- Brindle, K. (2008). New approaches for imaging tumour responses to treatment. *Nat. Rev. Cancer* **8**, 94-107.
- Buttar, N. S., Wang, K. K., Anderson, M. A., Dierkhising, R. A., Pacifico, R. J., Krishnadath, K. K. and Lutzke, L. S. (2002a). The effect of selective cyclooxygenase-2 inhibition in Barrett's esophagus epithelium: an in vitro study. *J. Natl. Cancer Inst.* **94**, 422-429.
- Buttar, N. S., Wang, K. K., Leontovich, O., Westcott, J. Y., Pacifico, R. J., Anderson, M. A., Krishnadath, K. K., Lutzke, L. S. and Burgart, L. J. (2002b). Chemoprevention of esophageal adenocarcinoma by COX-2 inhibitors in an animal model of Barrett's esophagus. *Gastroenterology* **122**, 1101-1112.
- Canto, M. I., Setrakian, S., Willis, J. E., Chak, A., Petras, R. E. and Sivak, M. V. (2001). Methylene blue staining of dysplastic and nondysplastic Barrett's esophagus: an in vivo and ex vivo study. *Endoscopy* **33**, 391-400.
- Casson, A. G., Zheng, Z., Evans, S. C., Geldenhuys, L., van Zanten, S. V., Veugelaers, P. J., Porter, G. A. and Guernsey, D. L. (2005). Cyclin D1 polymorphism (G870A) and risk for esophageal adenocarcinoma. *Cancer* **104**, 730-739.
- Casson, A. G., Zheng, Z., Porter, G. A. and Guernsey, D. L. (2006). Genetic polymorphisms of microsomal epoxide hydroxylase and glutathione S-transferases M1, T1 and P1, interactions with smoking, and risk for esophageal (Barrett) adenocarcinoma. *Cancer Detect. Prev.* **30**, 423-431.
- Chang, C. L., Lao-Sirieix, P., Save, V., De La Cueva Mendez, G., Laskey, R. and Fitzgerald, R. C. (2007). Retinoic acid-induced glandular differentiation of the oesophagus. *Gut* **56**, 906-917.
- Conio, M., Cameron, A. J., Romero, Y., Branch, C. D., Schleck, C. D., Burgart, L. J., Zinsmeister, A. R., Melton, L. J., 3rd and Locke, G. R., 3rd (2001). Secular trends in the epidemiology and outcome of Barrett's oesophagus in Olmsted County, Minnesota. *Gut* **48**, 304-309.
- Corder, A. P., Jones, R. H., Sadler, G. H., Daniels, P. and Johnson, C. D. (1996). Heartburn, oesophagitis and Barrett's oesophagus in self-medicating patients in general practice. *Br. J. Clin. Pract.* **50**, 245-248.
- Crane, S. J., Richard Locke, G., 3rd, Harmsen, W. S., Diehl, N. N., Zinsmeister, A. R., Joseph Melton, L., 3rd, Romero, Y. and Talley, N. J. (2007). The changing incidence of oesophageal and gastric adenocarcinoma by anatomic sub-site. *Aliment. Pharmacol. Ther.* **25**, 447-453.
- Curvers, W. L., Singh, R., Song, L. M., Wolfsen, H. C., Ragunath, K., Wang, K., Wallace, M. B., Fockens, P. and Bergman, J. J. (2008). Endoscopic tri-modal imaging for detection of early neoplasia in Barrett's oesophagus: a multi-centre feasibility study using high-resolution endoscopy, autofluorescence imaging and narrow band imaging incorporated in one endoscopy system. *Gut* **57**, 167-172.
- di Martino, E., Hardie, L. J., Wild, C. P., Gong, Y. Y., Olliver, J. R., Gough, M. D. and Bird, N. C. (2007). The NAD(P)H:quinone oxidoreductase I C609T polymorphism modifies the risk of Barrett esophagus and esophageal adenocarcinoma. *Genet. Med.* **9**, 341-347.
- Fernando, H. C., Luketich, J. D., Buenaventura, P. O., Perry, Y. and Christie, N. A. (2002). Outcomes of minimally invasive esophagectomy (MIE) for high-grade dysplasia of the esophagus. *Eur. J. Cardiothorac. Surg.* **22**, 1-6.
- Fitzgerald, R. C. (2006). Molecular basis of Barrett's oesophagus and oesophageal adenocarcinoma. *Gut* **55**, 1810-1820.
- Fortun, P. J., Anagnostopoulos, G. K., Kaye, P., James, M., Foley, S., Samuel, S., Shonde, A., Badreldin, R., Campbell, E., Hawkey, C. J. et al. (2006). Acetic acid enhanced magnification endoscopy in the diagnosis of specialized intestinal metaplasia, dysplasia and early cancer in Barrett's oesophagus. *Aliment. Pharmacol. Ther.* **23**, 735-742.
- Frese, K. K. and Tuveson, D. A. (2008). Maximizing mouse cancer models. *Nat. Rev. Cancer* **7**, 645-658.
- Galipeau, P. C., Li, X., Blount, P. L., Maley, C. C., Sanchez, C. A., Odze, R. D., Ayub, K., Rabinovitch, P. S., Vaughan, T. L. and Reid, B. J. (2007). NSAIDs modulate CDKN2A, TP53, and DNA content risk for progression to esophageal adenocarcinoma. *PLoS Med.* **4**, e67.
- Gedder, H., Zeriouh, M., Wolter, M., Heise, J. W., Gabbert, H. E. and Sarbia, M. (2002). Gene amplification and protein overexpression of c-erb-b2 in Barrett carcinoma and its precursor lesions. *Am. J. Clin. Pathol.* **118**, 60-66.
- Gerson, L. B., Shetler, K. and Triadafilopoulos, G. (2002). Prevalence of Barrett's esophagus in asymptomatic individuals. *Gastroenterology* **123**, 461-467.
- Ibrahim, N. B. (2000). ACP Best Practice No 155. Guidelines for handling oesophageal biopsies and resection specimens and their reporting. *J. Clin. Pathol.* **53**, 89-94.
- Izzo, J. G., Wu, T. T., Wu, X., Ensor, J., Luthra, R., Pan, J., Correa, A., Swisher, S. G., Chao, C. K., Hittelman, W. N. et al. (2007). Cyclin D1 guanine/adenine 870 polymorphism with altered protein expression is associated with genomic instability and aggressive clinical biology of esophageal adenocarcinoma. *J. Clin. Oncol.* **25**, 698-707.
- Kerkhof, M., van Dekken, H., Steyerberg, E. W., Meijer, G. A., Mulder, A. H., de Bruine, A., Driessen, A., ten Kate, F. J., Kusters, J. G., Kuipers, E. J. et al. (2007). Grading of dysplasia in Barrett's oesophagus: substantial interobserver variation between general and gastrointestinal pathologists. *Histopathology* **50**, 920-927.
- Lao-Sirieix, P., Lovat, L. and Fitzgerald, R. C. (2007). Cyclin A immunocytology as a risk stratification tool for Barrett's esophagus surveillance. *Clin. Cancer Res.* **13**, 659-665.
- Leadham, S. J., Preston, S. L., McDonald, S. A., Elia, G., Bhandari, P., Poller, D., Harrison, R., Novelli, M. R., Jankowski, J. A. and Wright, N. A. (2008). Individual crypt genetic heterogeneity and the origin of metaplastic glandular epithelium in human Barrett's oesophagus. *Gut* 27 Feb [Epub ahead of print].
- Lovat, L. B., Johnson, K., Mackenzie, G. D., Clark, B. R., Novelli, M. R., Davies, S., O'Donovan, M., Selvasekar, C., Thorpe, S. M., Pickard, D. et al. (2006). Elastic scattering spectroscopy accurately detects high grade dysplasia and cancer in Barrett's oesophagus. *Gut* **55**, 1078-1083.
- Murray, L., Sedo, A., Scott, M., McManus, D., Sloan, J. M., Hardie, L. J., Forman, D. and Wild, C. P. (2006). TP53 and progression from Barrett's metaplasia to oesophageal adenocarcinoma in a UK population cohort. *Gut* **55**, 1390-1397.
- Oda, D., Savard, C. E., Eng, L., Sekijima, J., Haigh, G. and Lee, S. P. (1998). Reconstituted human oral and esophageal mucosa in culture. *In Vitro Cell. Dev. Biol. Anim.* **34**, 46-52.
- Okawa, T., Michaylira, C. Z., Kalabis, J., Stairs, D. B., Nakagawa, H., Andl, C. D., Johnstone, C. N., Klein-Szanto, A. J., El-Deiry, W. S., Cukierman, E. et al. (2007). The functional interplay between EGFR overexpression, hTERT activation, and p53 mutation in esophageal epithelial cells with activation of stromal fibroblasts induces tumor development, invasion, and differentiation. *Genes Dev.* **21**, 2788-2803.
- Pepe, M. S., Etzioni, R., Feng, Z., Potter, J. D., Thompson, M. L., Thornquist, M., Winget, M. and Yasui, Y. (2001). Phases of biomarker development for early detection of cancer. *J. Natl. Cancer Inst.* **93**, 1054-1061.
- Playford, R. J. (2006). New British Society of Gastroenterology (BSG) guidelines for the diagnosis and management of Barrett's oesophagus. *Gut* **55**, 442.
- Powell, J., McConkey, C. C., Gillison, E. W. and Spychal, R. T. (2002). Continuing rising trend in oesophageal adenocarcinoma. *Int. J. Cancer* **102**, 422-427.
- Redon, R., Ishikawa, S., Fitch, K. R., Feuk, L., Perry, G. H., Andrews, T. D., Fiegler, H., Shaperro, M. H., Carson, A. R., Chen, W. et al. (2006). Global variation in copy number in the human genome. *Nature* **444**, 444-454.

- Ronkainen, J., Aro, P., Storskrubb, T., Johansson, S. E., Lind, T., Bolling-Sternevald, E., Vieth, M., Stolte, M., Talley, N. J. and Agreus, L.** (2005). Prevalence of Barrett's esophagus in the general population: an endoscopic study. *Gastroenterology* **129**, 1825-1831.
- Sampliner, R. E.** (2002). Updated guidelines for the diagnosis, surveillance, and therapy of Barrett's esophagus. *Am. J. Gastroenterol.* **97**, 1888-1895.
- Schulmann, K., Sterian, A., Berki, A., Yin, J., Sato, F., Xu, Y., Olaru, A., Wang, S., Mori, Y., Deacu, E. et al.** (2005). Inactivation of p16, RUNX3, and HPP1 occurs early in Barrett's-associated neoplastic progression and predicts progression risk. *Oncogene* **24**, 4138-4148.
- Shaheen, N. J., Crosby, M. A., Bozymski, E. M. and Sandler, R. S.** (2000). Is there publication bias in the reporting of cancer risk in Barrett's esophagus? *Gastroenterology* **119**, 333-338.
- Sharma, V. K., Wang, K. K., Overholt, B. F., Lightdale, C. J., Fennerty, M. B., Dean, P. J., Pleskow, D. K., Chuttani, R., Reymunde, A., Santiago, N. et al.** (2007). Balloon-based, circumferential, endoscopic radiofrequency ablation of Barrett's esophagus: 1-year follow-up of 100 patients. *Gastrointest. Endosc.* **65**, 185-195.
- Shirvani, V. N., Ouatu-Lascar, R., Kaur, B. S., Omary, M. B. and Triadafilopoulos, G.** (2000). Cyclooxygenase 2 expression in Barrett's esophagus and adenocarcinoma: Ex vivo induction by bile salts and acid exposure. *Gastroenterology* **118**, 487-496.
- Sirieix, P. S., O'Donovan, M., Brown, J., Save, V., Coleman, N. and Fitzgerald, R. C.** (2003). Surface expression of minichromosome maintenance proteins provides a novel method for detecting patients at risk for developing adenocarcinoma in Barrett's esophagus. *Clin. Cancer Res.* **9**, 2560-2566.
- Solaymani-Dodaran, M., Logan, R. F., West, J., Card, T. and Coupland, C.** (2004). Risk of oesophageal cancer in Barrett's oesophagus and gastro-oesophageal reflux. *Gut* **53**, 1070-1074.
- Younes, M.** (2005). Is the incidence of esophageal adenocarcinomas in patients with Barrett's esophagus really overestimated? *Gastroenterology* **129**, 2125-2126; author reply 2126.
- Younes, M., Ertan, A., Lechago, L. V., Somoano, J. R. and Lechago, J.** (1997). p53 Protein accumulation is a specific marker of malignant potential in Barrett's metaplasia. *Dig. Dis. Sci.* **42**, 697-701.